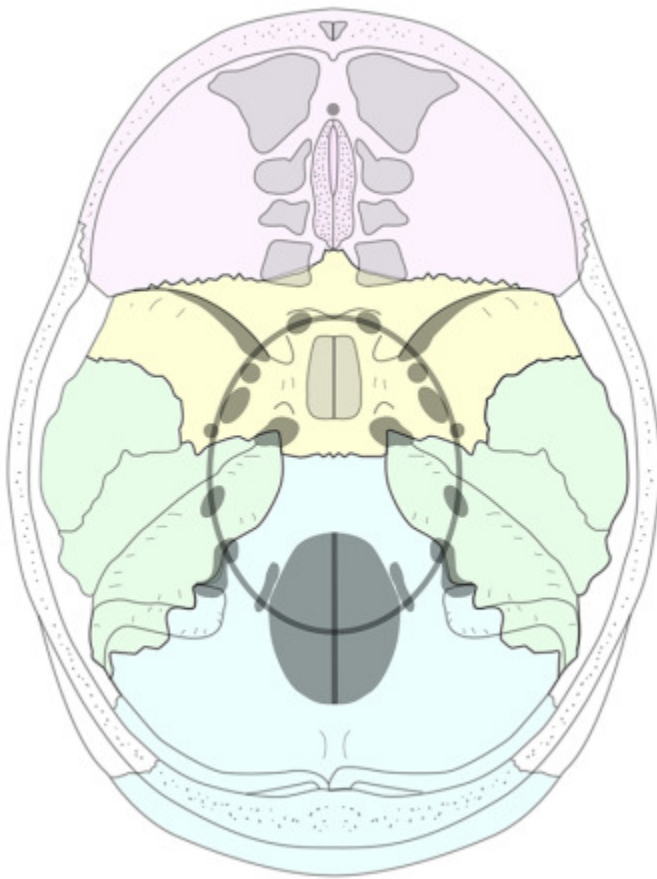
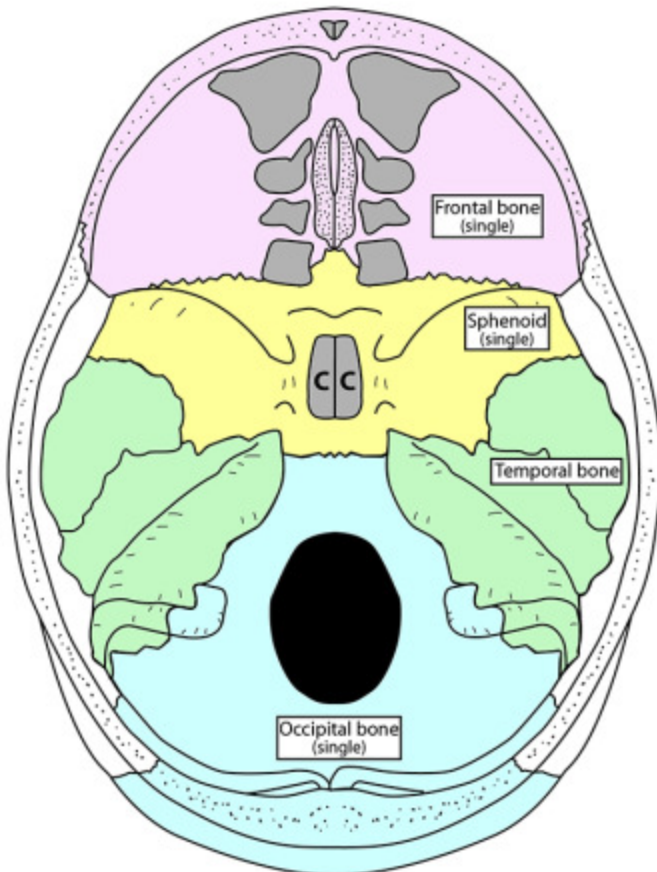


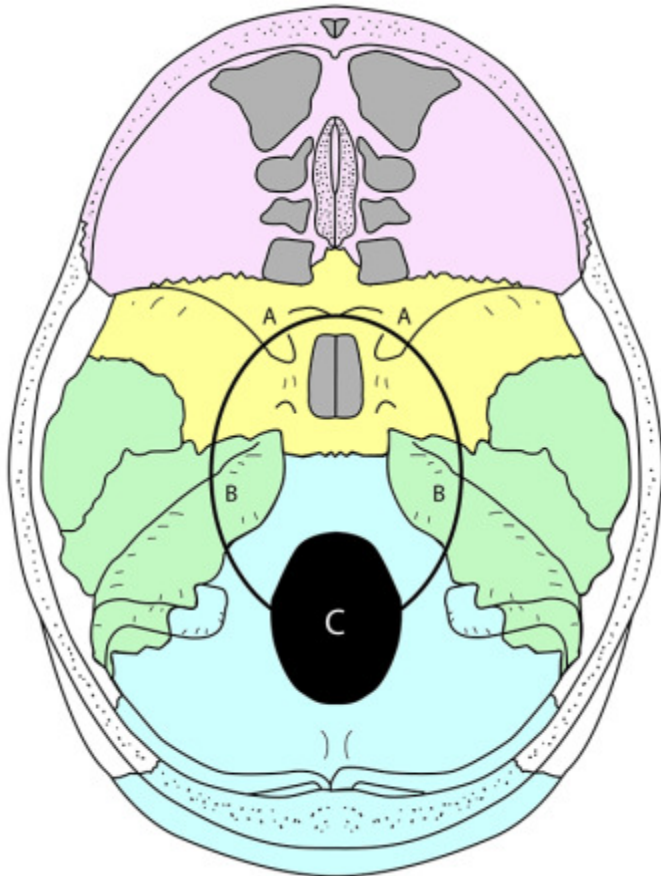
Skull Base Foramina



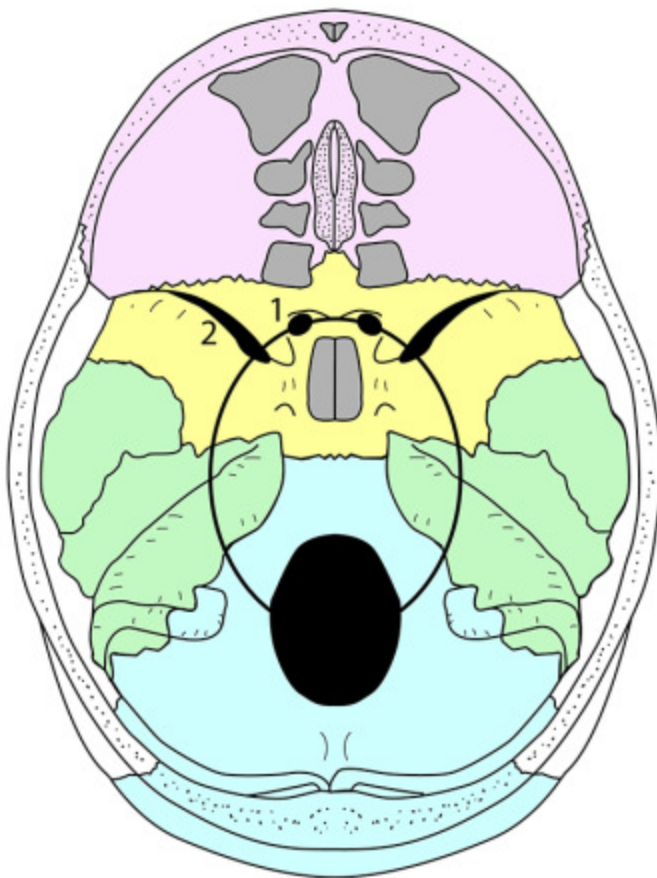
# SKULL FORAMINA



- AIR SINUSES
- A Frontal
  - B Ethmoidal
    - anterior
    - middle
    - posterior
  - C Sphenoidal

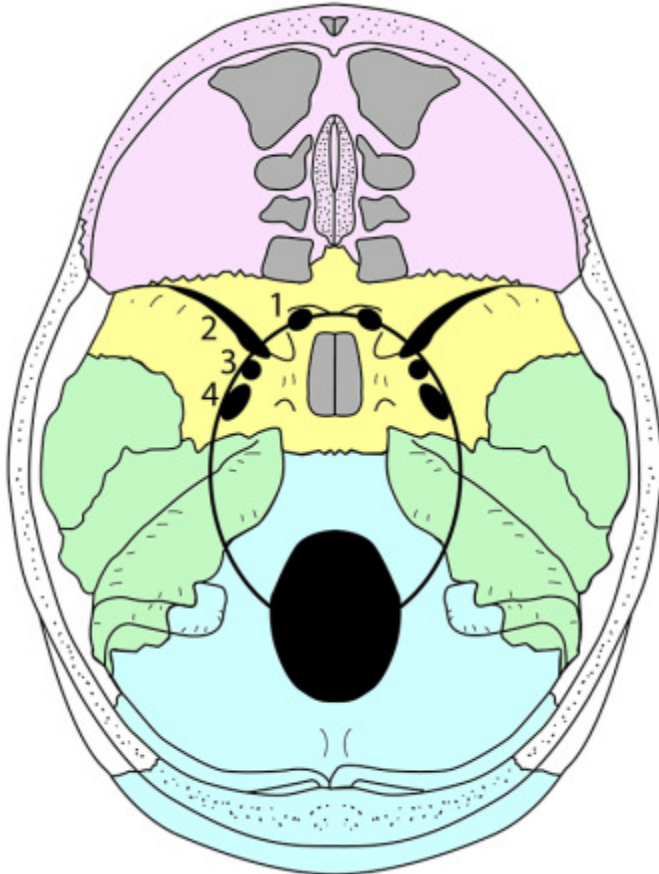


Draw a oval line that passes through the medial ends of the lesser wings of the sphenoid (A), the petrous temporal bones (B) and the centre of the foramen magnum (C). All but three of the important internal skull foramina lie on this line.



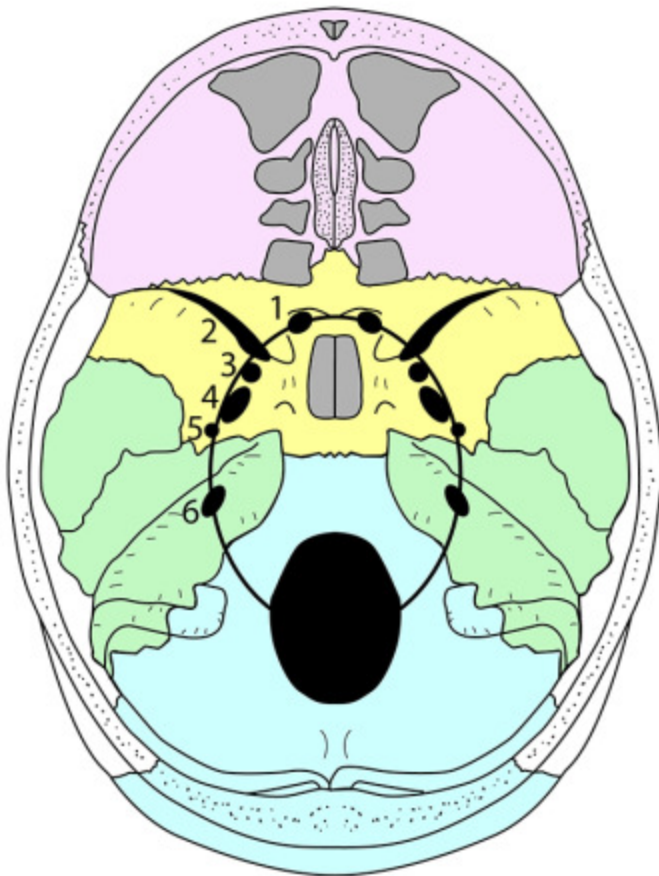
### FORAMINA

- 1    Optic canal
- 2    Superior orbital fissure



**FORAMINA**

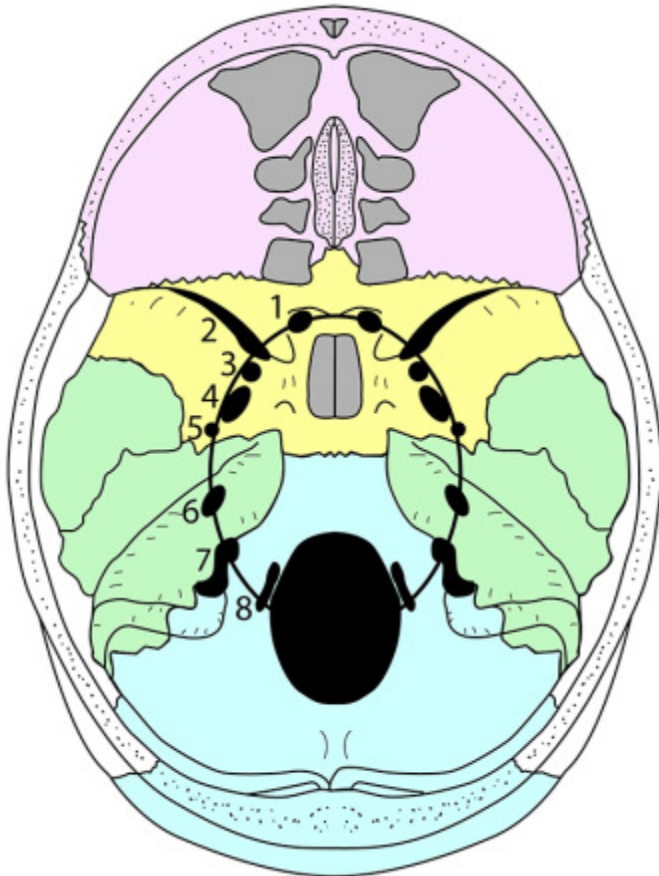
- 1 Optic canal
- 2 Superior orbital fissure
- 3 Foramen rotundum
- 4 Foramen ovale



**FORAMINA**

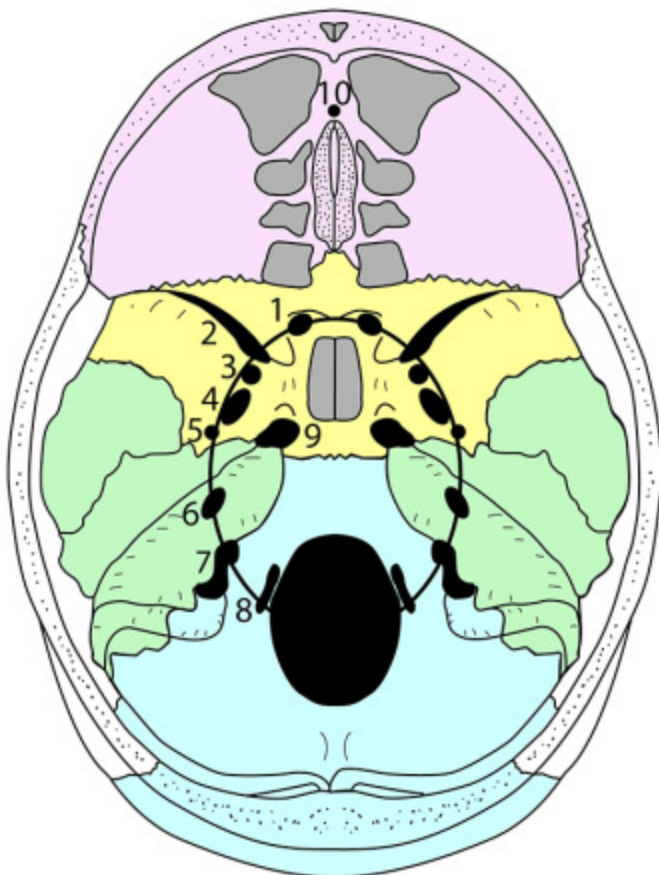
- 1 Optic canal
- 2 Superior orbital fissure
- 3 Foramen rotundum
- 4 Foramen ovale
- 5 Foramen spinosum
- 6 Internal acoustic (auditory) meatus





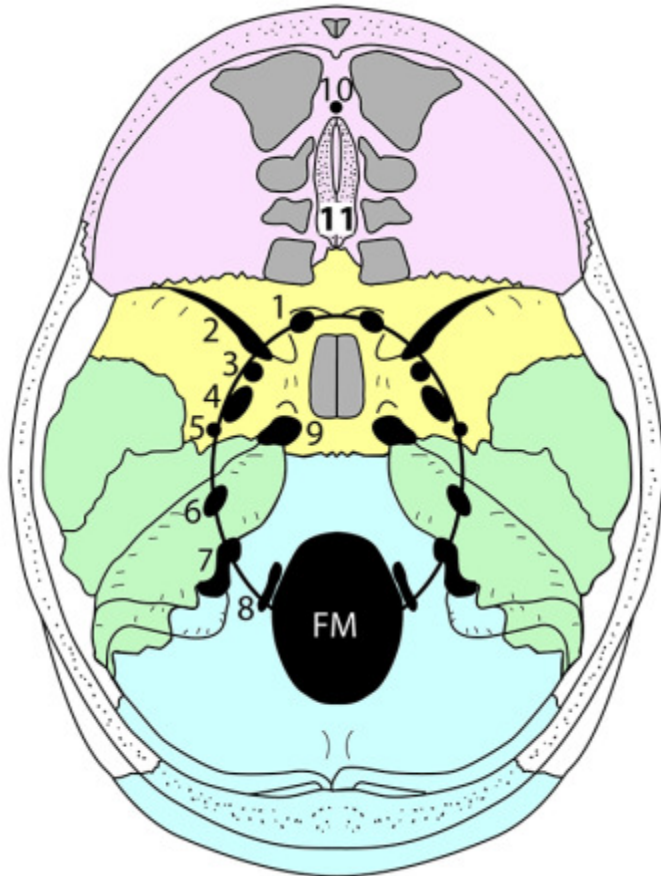
### FORAMINA

- 1 Optic canal
- 2 Superior orbital fissure
- 3 Foramen rotundum
- 4 Foramen ovale
- 5 Foramen spinosum
- 6 Internal acoustic (auditory) meatus
- 7 Jugular foramen
- 8 Hypoglossal canal



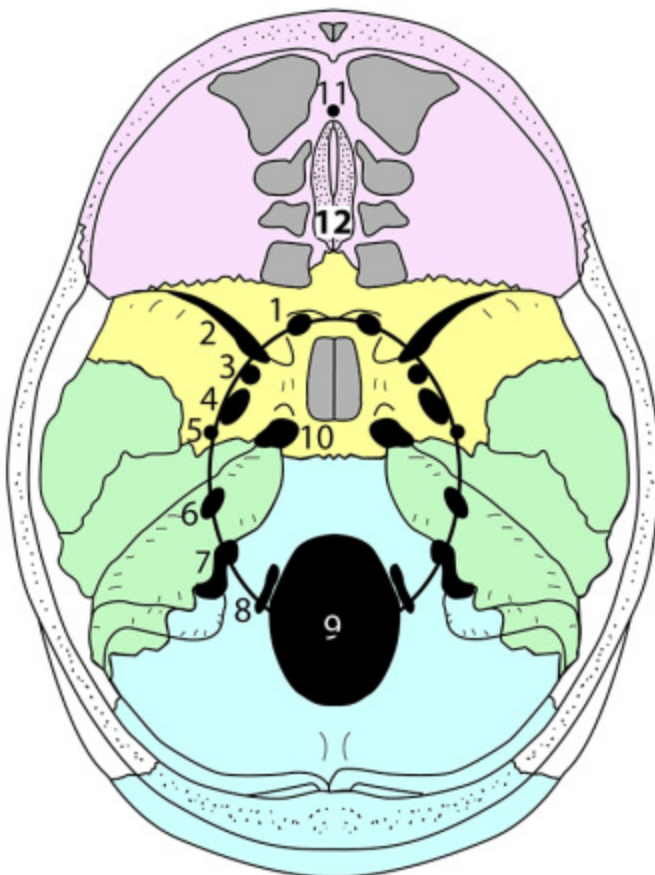
### FORAMINA

- 1 Optic canal
- 2 Superior orbital fissure
- 3 Foramen rotundum
- 4 Foramen ovale
- 5 Foramen spinosum
- 6 Internal acoustic (auditory) meatus
- 7 Jugular foramen
- 8 Hypoglossal canal
- 9 Foramen lacerum
- 10 Foramen caecum (single midline)



### FORAMINA

- 1 Optic canal
- 2 Superior orbital fissure
- 3 Foramen rotundum
- 4 Foramen ovale
- 5 Foramen spinosum
- 6 Internal acoustic (auditory) meatus
- 7 Jugular foramen
- 8 Hypoglossal canal
- 9 Foramen lacerum
- 10 Foramen caecum (single midline)
- 11 Cribriform plate of ethmoid
- FM Foramen magnum

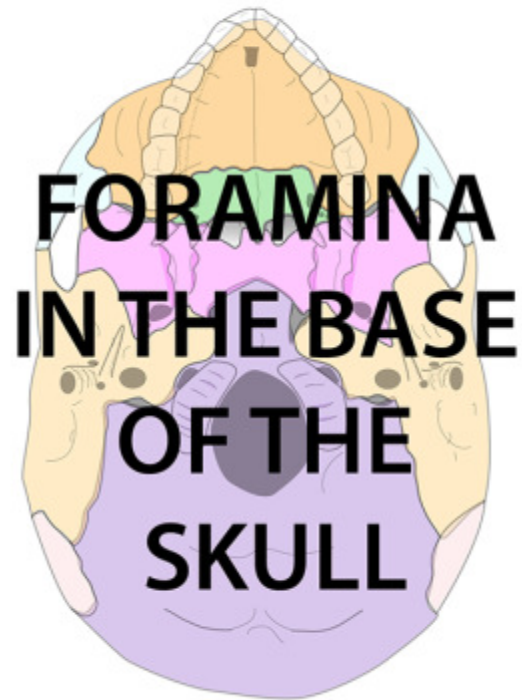


### FORAMINA ON OVAL LINE

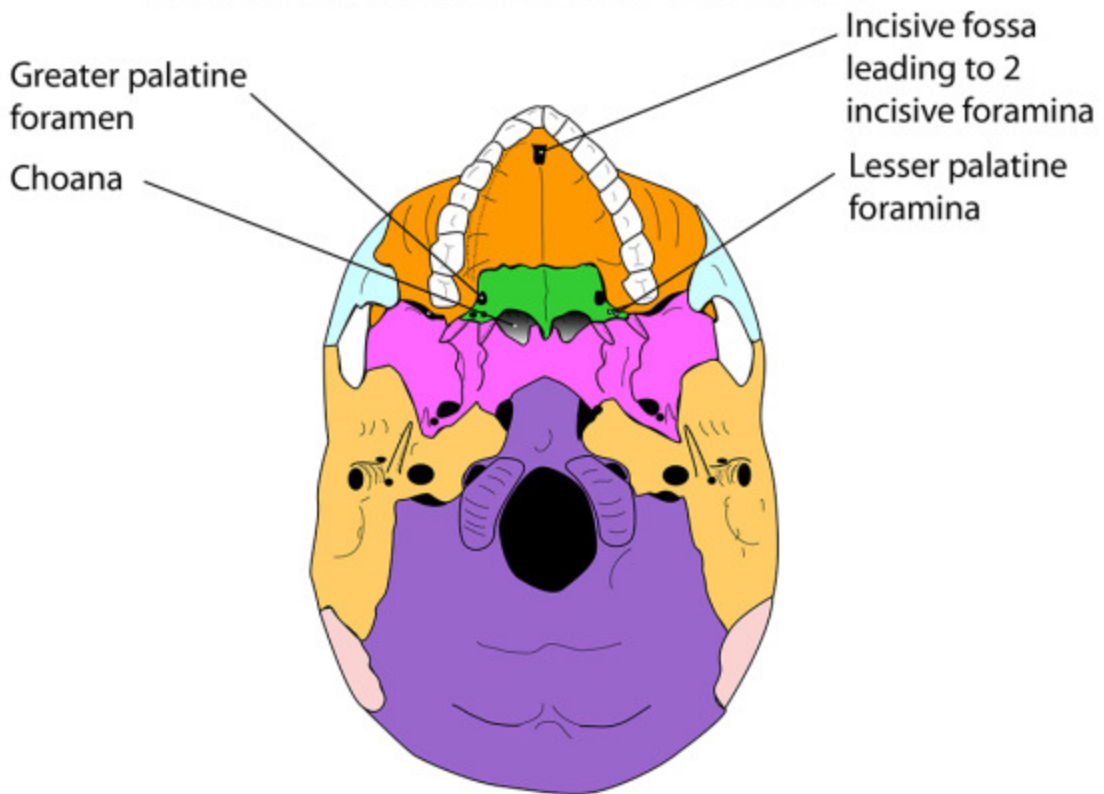
- 1 Optic canal
- 2 Superior orbital fissure
- 3 Foramen rotundum
- 4 Foramen ovale
- 5 Foramen spinosum
- 6 Internal acoustic (auditory) meatus
- 7 Jugular foramen
- 8 Hypoglossal canal
- 9 Foramen magnum

### FORAMINA NOT ON OVAL LINE

- 10 Foramen lacerum
- 11 Foramen caecum (single midline)
- 12 Cribriform plate of ethmoid

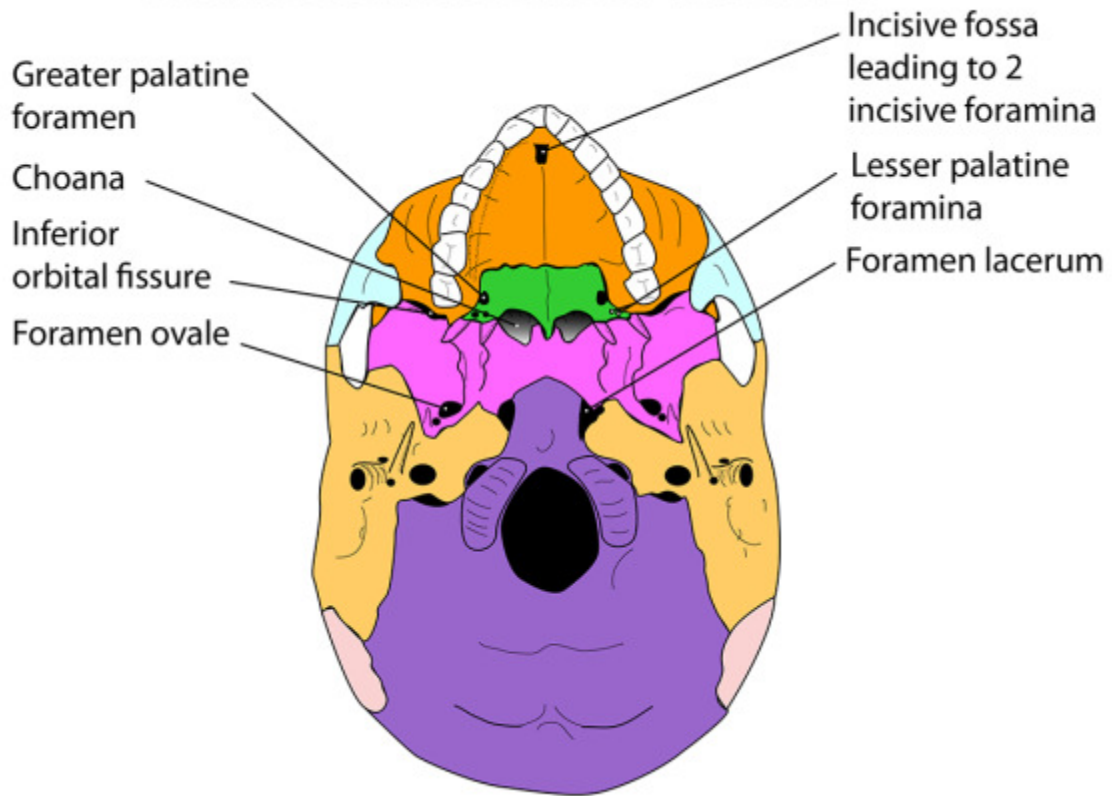


## FORAMINA IN THE BASE OF THE SKULL

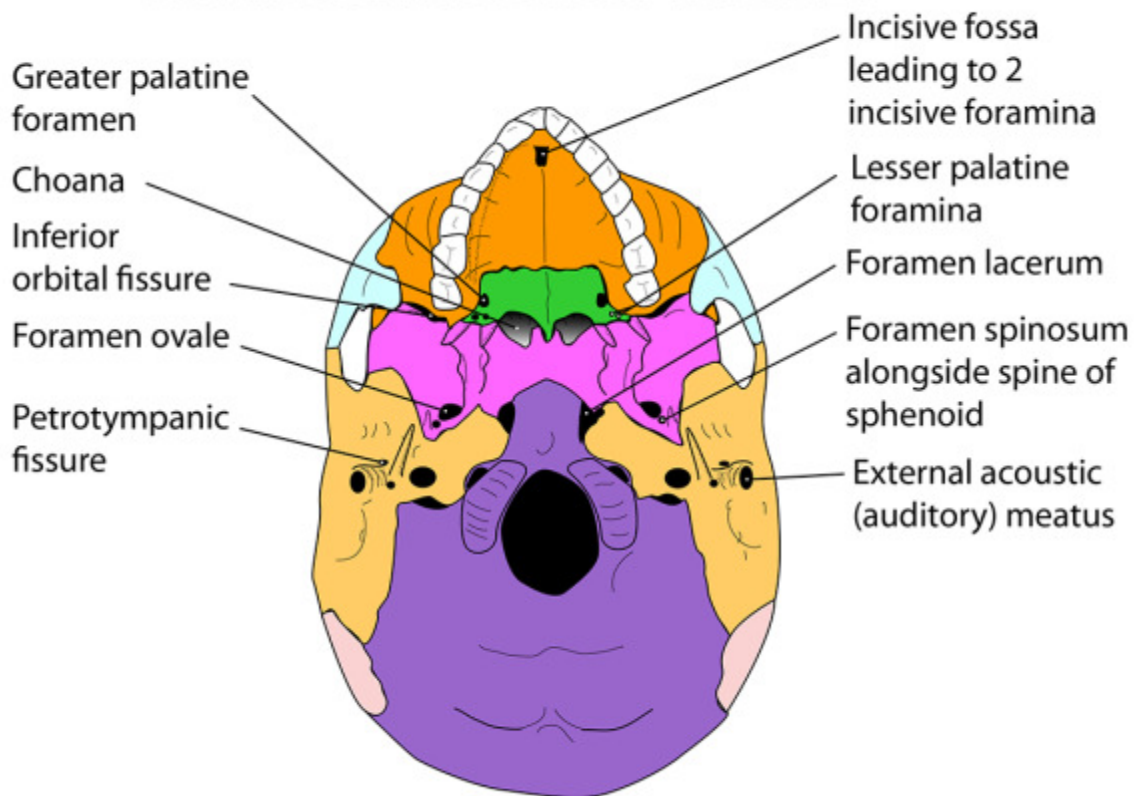




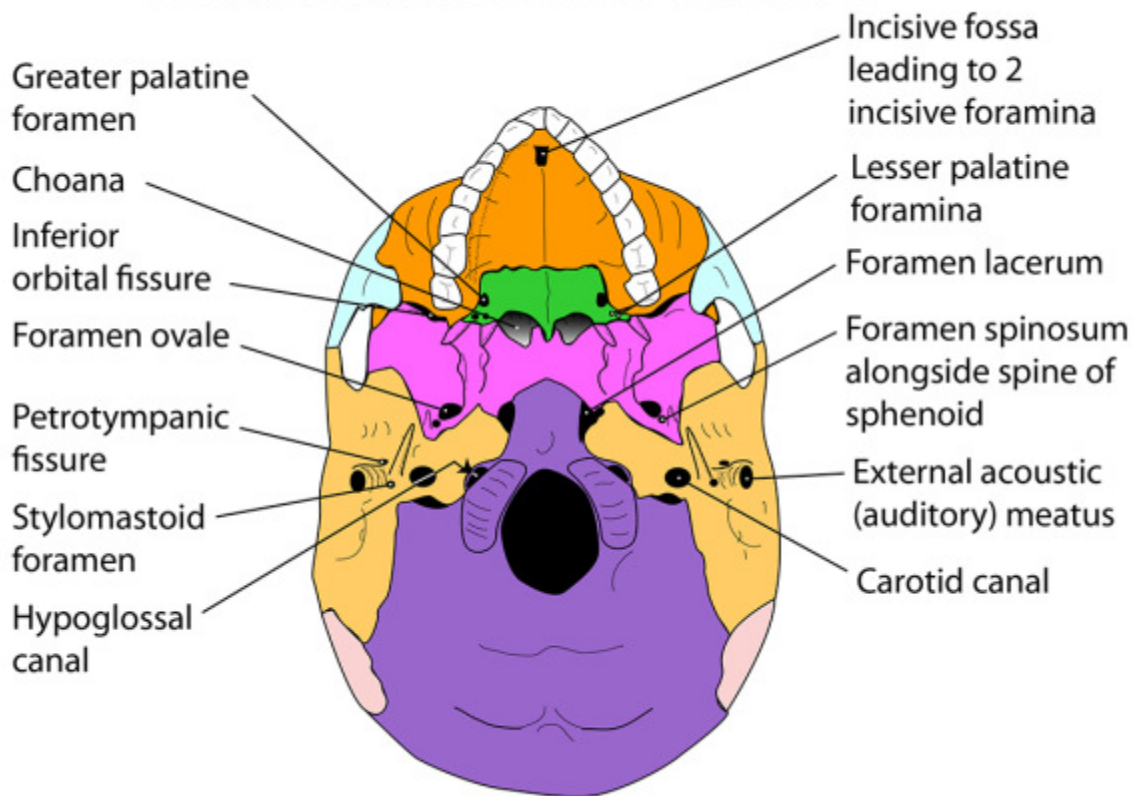
## FORAMINA IN THE BASE OF THE SKULL



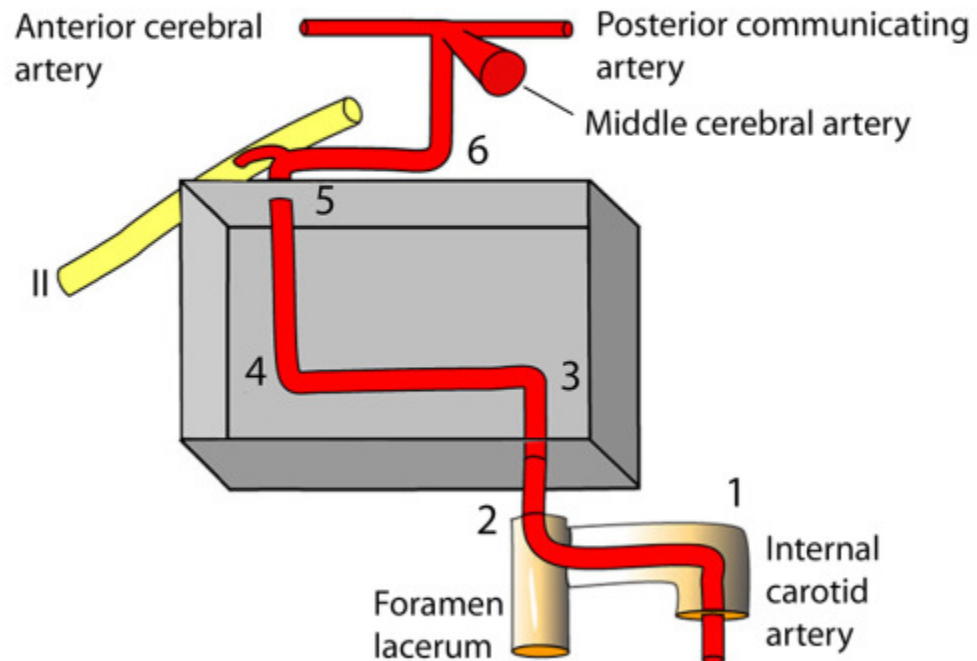
## FORAMINA IN THE BASE OF THE SKULL



## FORAMINA IN THE BASE OF THE SKULL



## DIAGRAMMATIC REPRESENTATION OF THE 6 BENDS OF THE INTERNAL CAROTID ARTERY





## FORAMINA IN THE BASE OF THE SKULL

