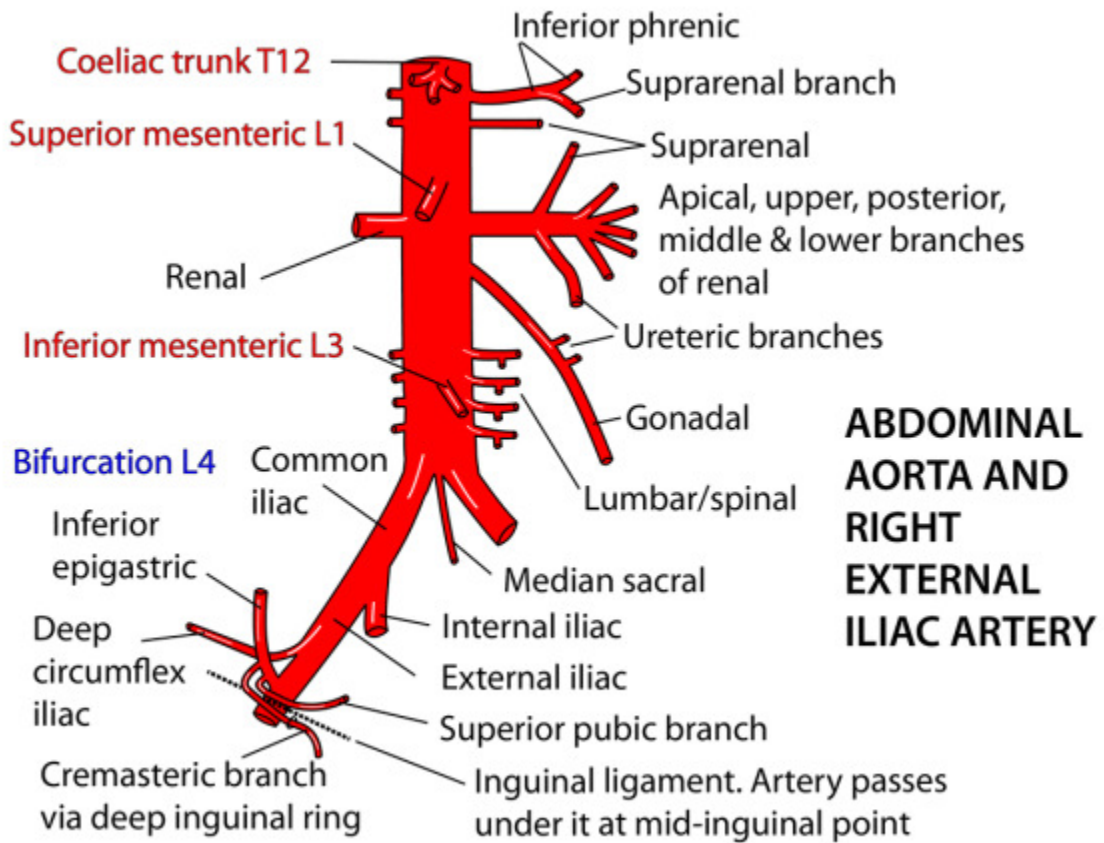
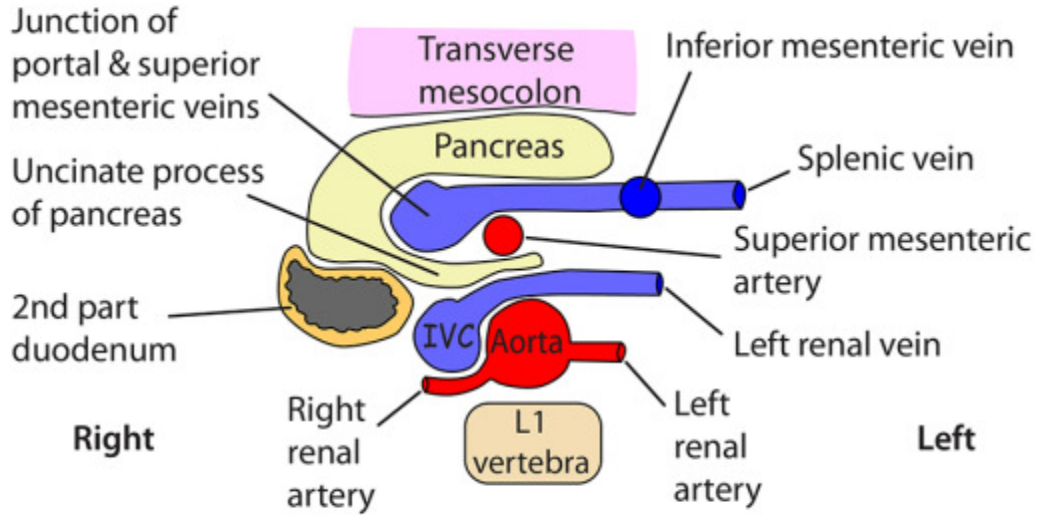


Abdominal Aorta & Bowel Blood Supply



AXIAL (CROSS) SECTION AT L1 LOOKING UP



LONGITUDINAL SECTION VIEWED FROM RIGHT

