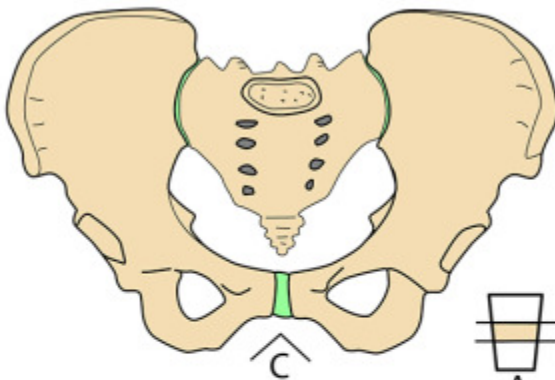


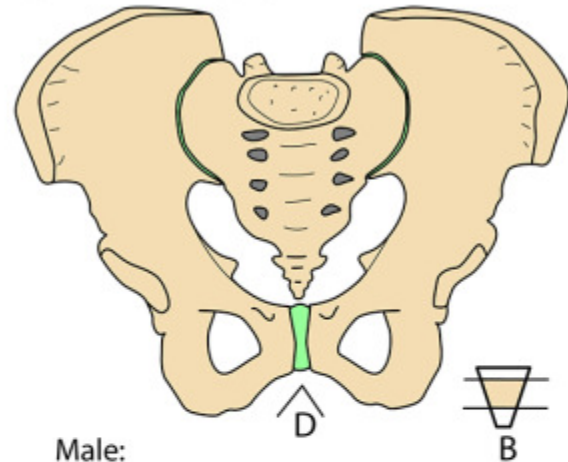
Sex Differences in Bony Pelvis

PELVIC BONES - SEX DIFFERENCES



Female:

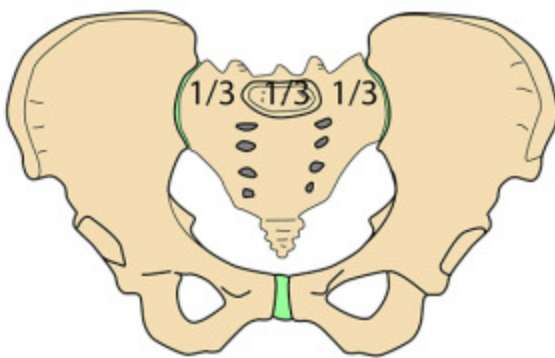
- Build - Less heavy
- Inlet rounded (gynaecoid)
- Short segment of long cone (A)
- Subpubic angle - >90 degrees (C)
- Obturator foramen - elongated/triangular
- Muscle markings +
- Wider between ischial spines



Male:

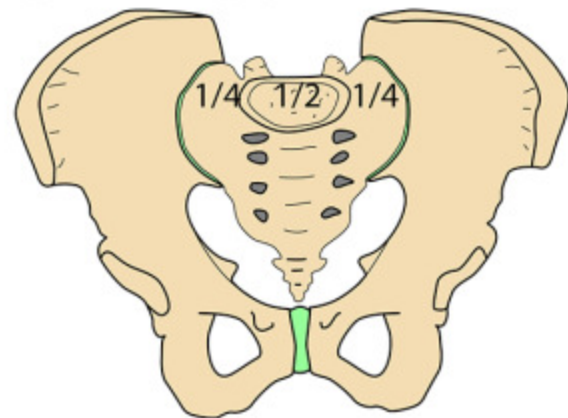
- Build - Heavy
- Inlet less rounded (android)
- Long segment of short cone (B)
- Subpubic angle - <90 degrees (D)
- Obturator fossa - rounded/oval
- Muscle markings +++
- Narrower between ischial spines

PELVIC BONES - SEX DIFFERENCES



Female:

- Width of L5 vertebra \vee each sacral ala - each $1/3$
- Greater sciatic notch - nearly a right angle
- Ischiopubic ramus - smooth
- Pubic tubercle to acetabular margin \vee diameter of acetabulum - greater



Male:

- Width of L5 vertebra \vee each sacral ala - $1/2$ to $1/4$
- Greater sciatic notch - less than a right angle (J shape)
- Ischiopubic ramus - rough (crura)
- Pubic tubercle to acetabular margin \vee diameter of acetabulum - equal or less