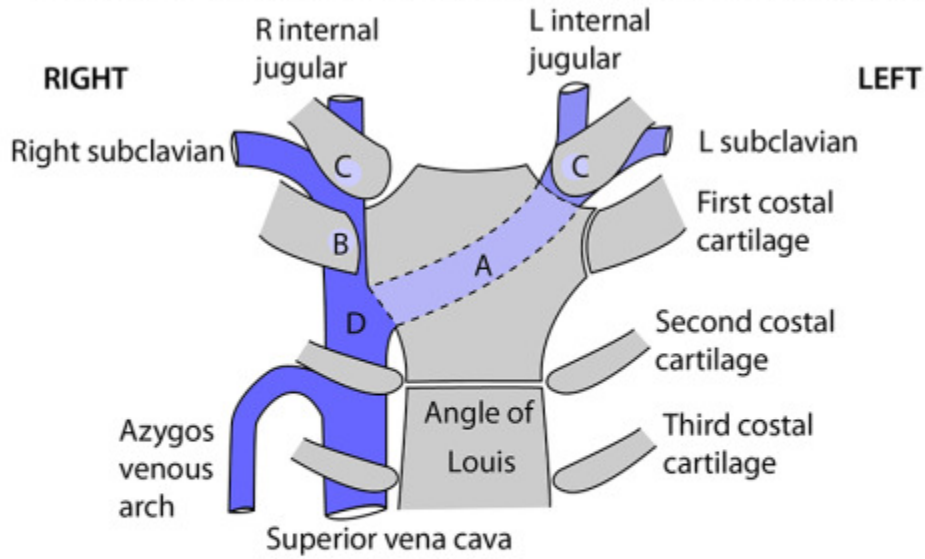
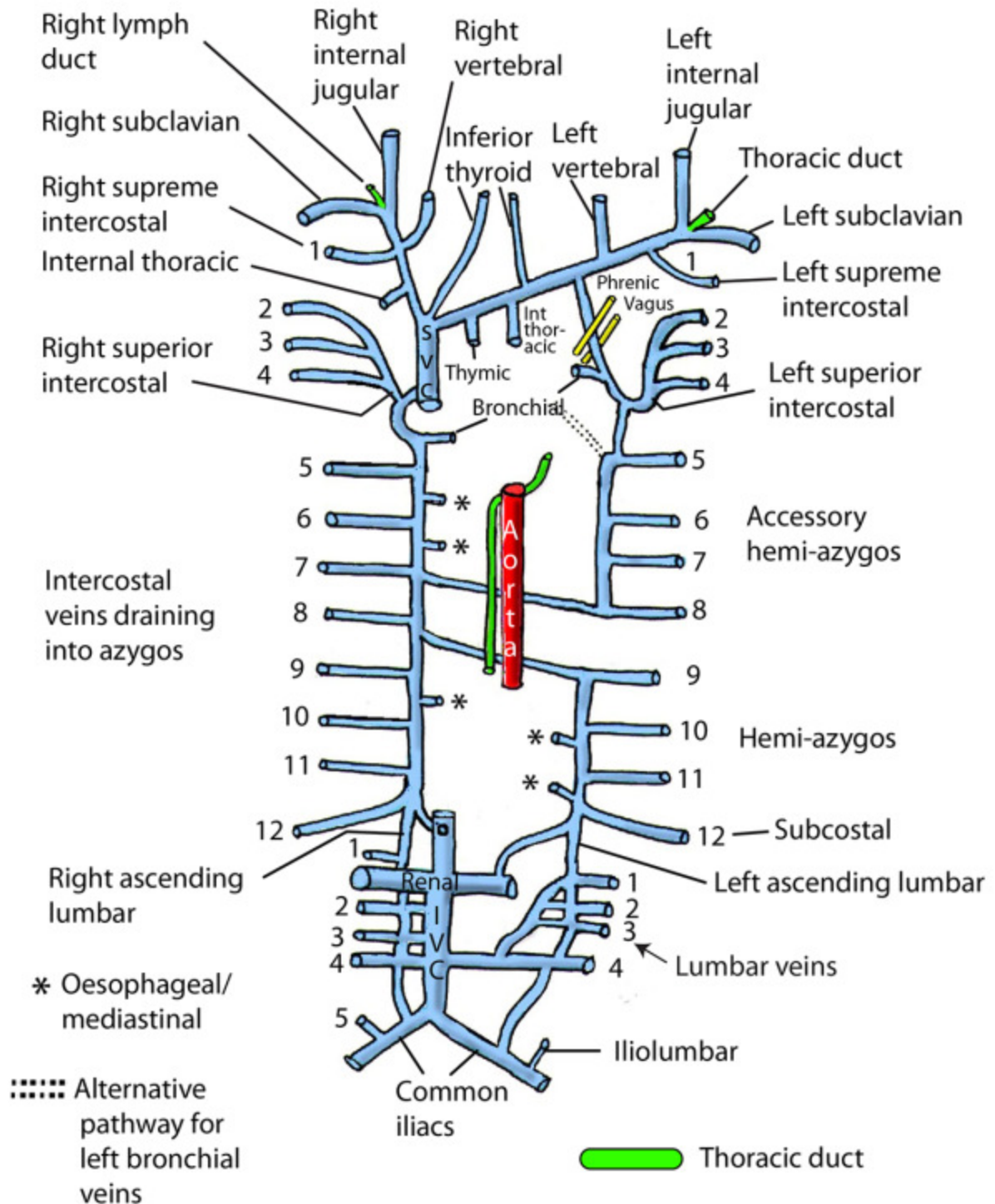


VEINS IN UPPER MEDIASTINUM AND LOWER NECK



- A Left brachiocephalic vein
- B Right brachiocephalic vein
- C Formation of brachiocephalic veins posterior to the sternoclavicular joints
- D Formation of the superior vena cava in the first right intercostal space, just inferior to the first costal cartilage

SUPERIOR VENA CAVA AND AZYGOS SYSTEMS



**Note: Left and right supreme intercostal veins
may drain into vertebral veins**

ALTERNATIVE VENOUS RETURN IN IVC BLOCKAGE

