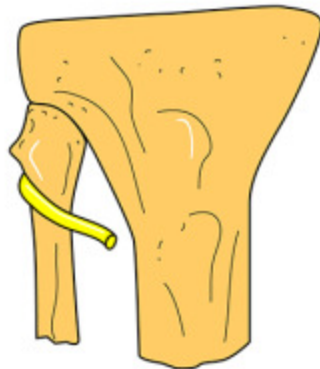


NERVE LESIONS IN THE LOWER LIMB 1

NERVES TO PSOAS & ILIACUS	No pelvic swing on walking
FEMORAL	Loss of hip flexion & knee extension Loss of sensation anterior thigh & medial leg
OBTURATOR	Loss of adduction of thigh Loss of sensation inner thigh
SUPERIOR GLUTEAL	Loss of abduction at hip. Pelvic dip on walking
INFERIOR GLUTEAL	Loss of extension at hip. Buttock wasting



**COMMON
FIBULAR
NERVE**

The common fibular nerve winds around the neck of the fibula before dividing into its deep and superficial branches. Pressure here from too tight a plaster or trauma can lead to a foot drop and sensory changes in the skin of the lateral lower leg and foot as seen in a L4/5 disc lesion involving the L5 root.

