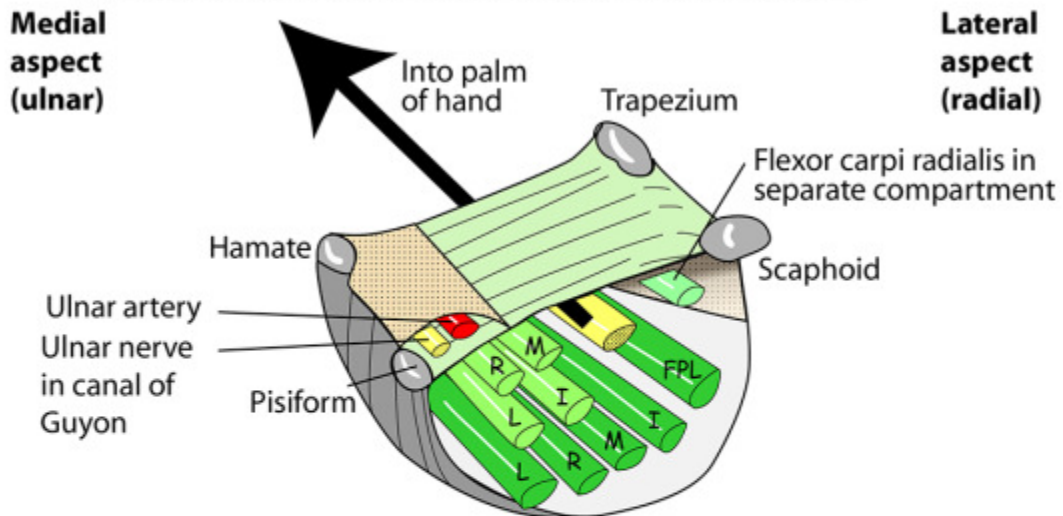


Flexor and Extensor Retinacula

FLEXOR RETINACULUM & CARPAL TUNNEL



Beneath (deep to) the flexor retinaculum

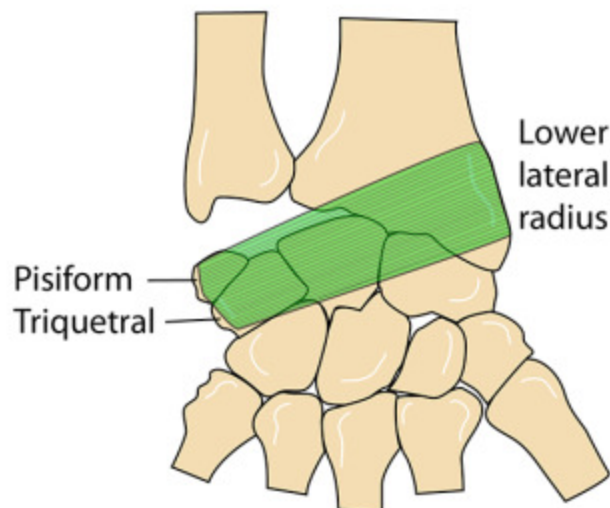
1. Median nerve
2. 4 tendons of flexor digitorum profundus
3. 4 tendons of flexor digitorum superficialis
4. Tendon of flexor pollicis longus
5. Flexor carpi radialis (in its own compartment)

Superficial to the flexor retinaculum

1. Ulnar nerve and ulnar artery (in their own tunnel (**Canal of Guyon**))
2. Palmar cutaneous branch of median nerve

RIGHT EXTENSOR RETINACULUM

Attachments



2.5cm wide, oblique, ribbon-like band
 Attached from radial styloid to pisiform & triquetral (NOT ulna)
 Fibrous septa to give 6 compartments