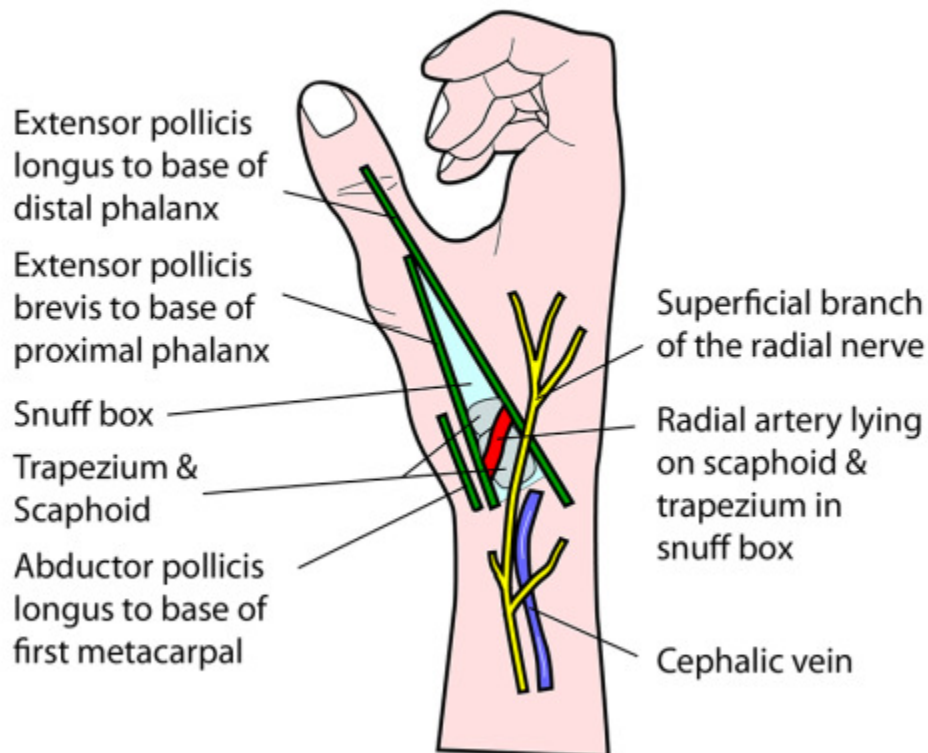
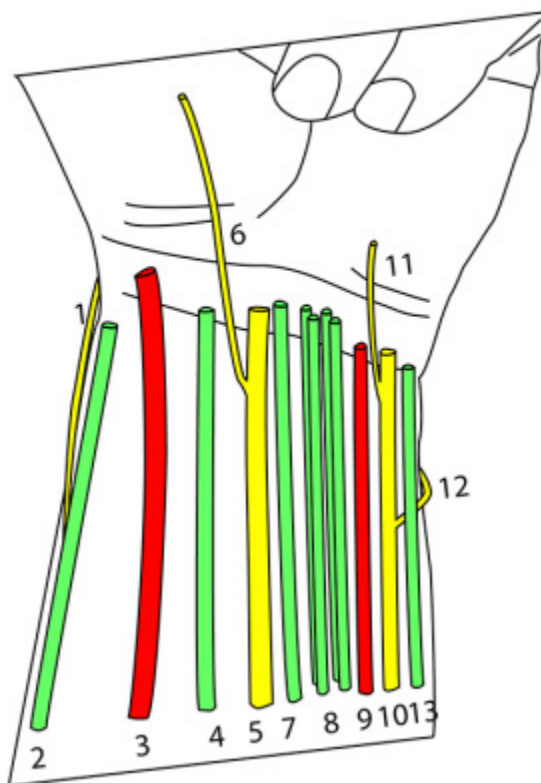


## ANATOMICAL SNUFF BOX



## VENTRAL ASPECT OF WRIST



### Structures radial to ulnar side:

- 1 Superficial branch of the radial nerve (emerging posterior to brachioradialis)
- 2 Brachioradialis
- 3 Radial artery
- 4 Flexor carpi radialis
- 5 Median nerve with its palmar cutaneous branch (6)
- 7 Palmaris longus
- 8 Flexor digitorum superficialis (4 tendons)
- 9 Ulnar artery
- 10 Ulnar nerve with its palmar cutaneous branch (11) & dorsal cutaneous branch (12)
- 13 Flexor carpi ulnaris