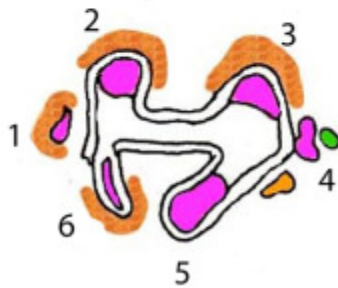
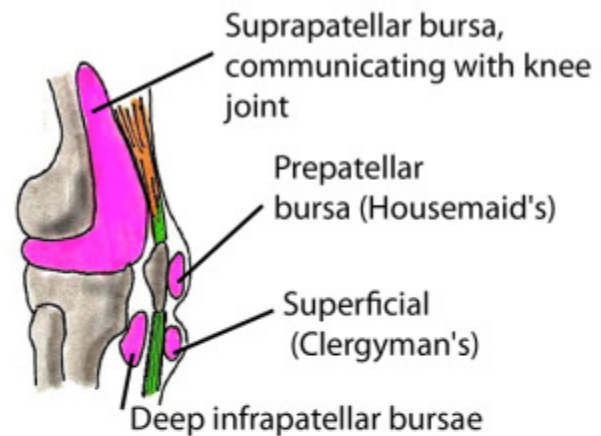


## Bursae and the Popliteal Fossa

### BURSAE AROUND KNEE

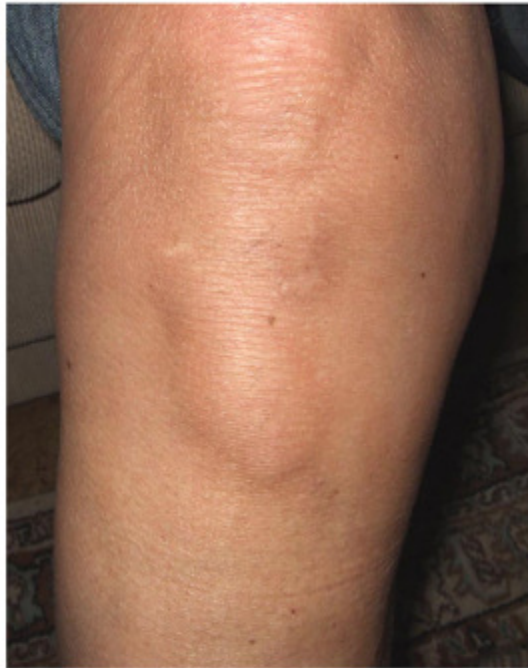

Tibial plateau to show how the synovium is attached to its edges but the cruciate ligaments lie outside it



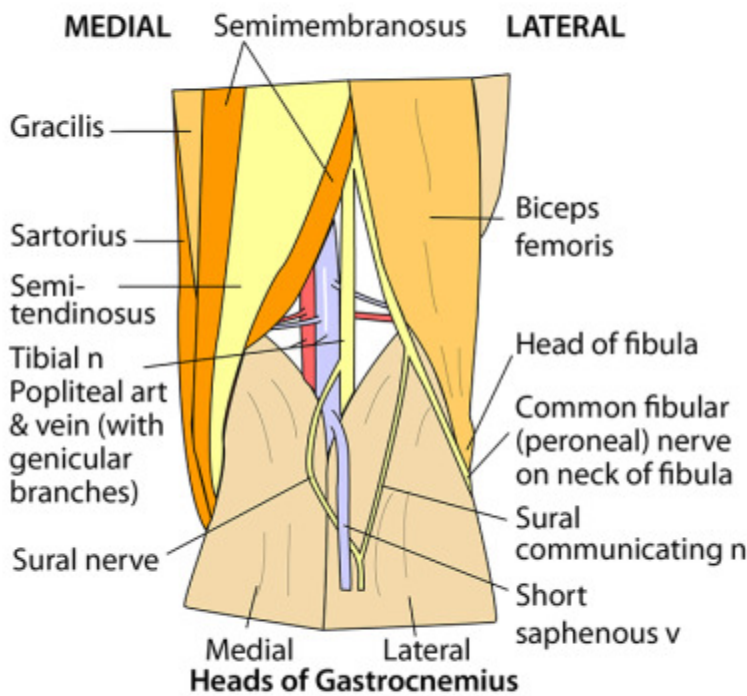
### Bursae - tendons and muscles

1. Under sartorius, gracilis, semitendinosus
2. Under medial head of gastrocnemius (often communicating with knee joint)
3. Under lateral head of gastrocnemius (sometimes into joint)
4. Under lateral collateral ligament
5. Under popliteus (into joint)
6. Under semimembranosus



**A SUPERFICIAL INFRAPATELLAR BURSA**

**RIGHT POPLITEAL REGION**



The popliteal fossa is bounded inferiorly by the two heads of gastrocnemius and superiorly by biceps femoris (laterally) and semitendinosus and semimembranosus (medially).

Note that the popliteal artery is the deepest structure in the fossa and hence the popliteal artery is often difficult to palpate

Anterior to artery are back of femur, capsule of knee joint and popliteus