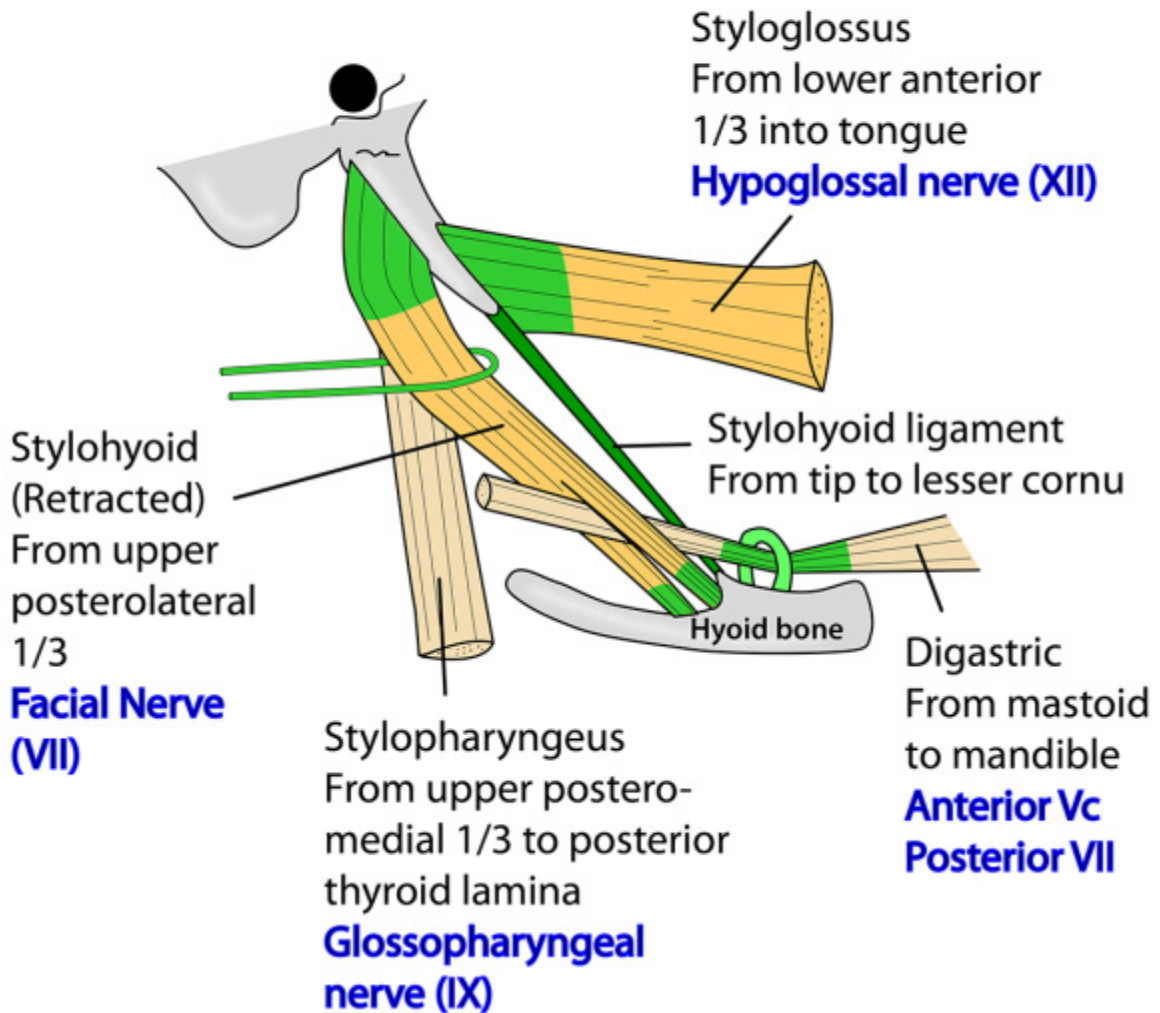


The Styloid process, infratempo

RIGHT STYLOID PROCESS MUSCLE AND LIGAMENT ATTACHMENTS LATERAL VIEW

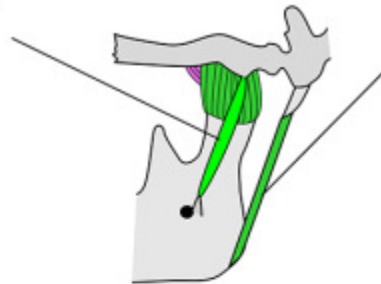


ral fossa and mandible

LIGAMENTS ASSOCIATED WITH MANDIBLE AND HYOID BONES

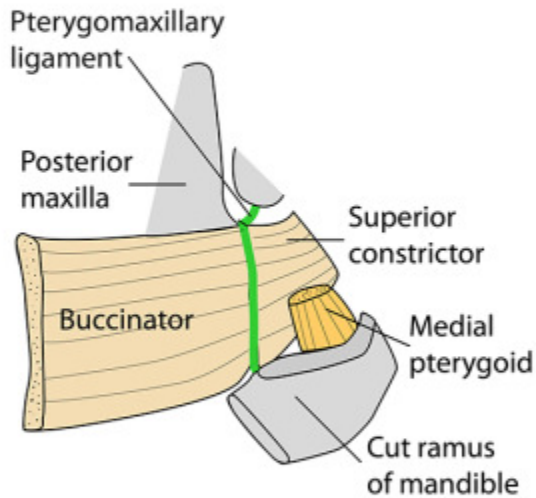
SPHENOMANDIBULAR LIGAMENT

Spine of sphenoid to lingula of mandible (1st arch remnant)
Is axis of rotation for opening of mouth



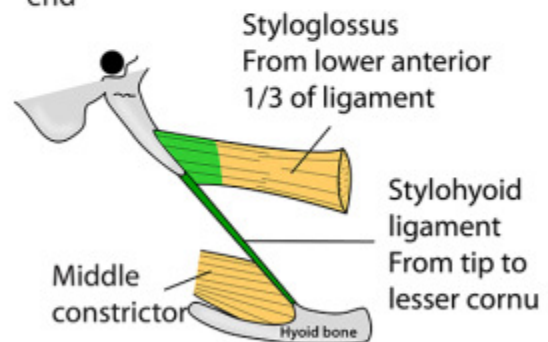
STYLOMANDIBULAR LIGAMENT

Specialised band of deep cervical fascia. Styloid process to angle of mandible. Is the postero-inferior aspect of the parotid fascia



STYLOHYOID LIGAMENT

Styloid process to lesser cornu of hyoid. 2nd arch remnant. Styloglossus from its upper end & middle constrictor from its lower end

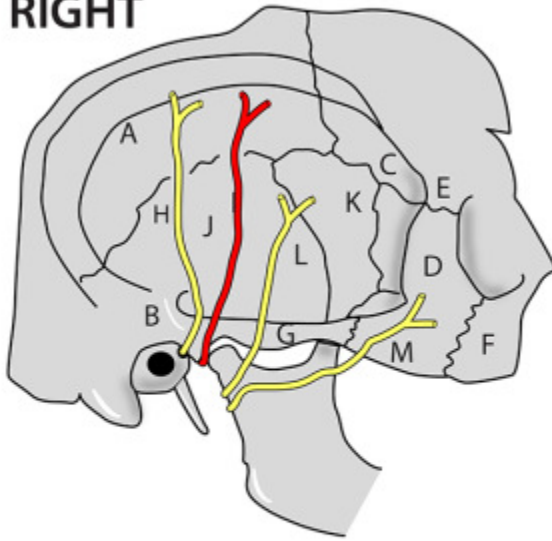


PTERYGOMANDIBULAR RAPHE

Tendinous muscle fibres from pterygoid hamulus to posterior end of mylohyoid line. Medially lies buccal mucosa. Superior constrictor arises posteriorly & buccinator anteriorly from it. Buccinator also extends onto the pterygomaxillary ligament to reach the maxilla

TEMPORAL FOSSA

RIGHT



Medial to temporalis - attached inferior to inferior temporal line (A)

Roof: Temporalis fascia

Posterior: Supramastoid crest (B)

Floor: Skull - pterion (C)

Anterior: Zygoma (D), zygomatic process of frontal bone (E) & zygomatic process of maxilla (F)

Inferior: Zygomatic arch & zygomatic process of temporal bone (G)

Contains: Temporalis, deep temporal arteries (maxillary), deep temporal nerves (Vc), Superficial temporal artery (external carotid).

Auriculotemporal nerve (H) from Vc

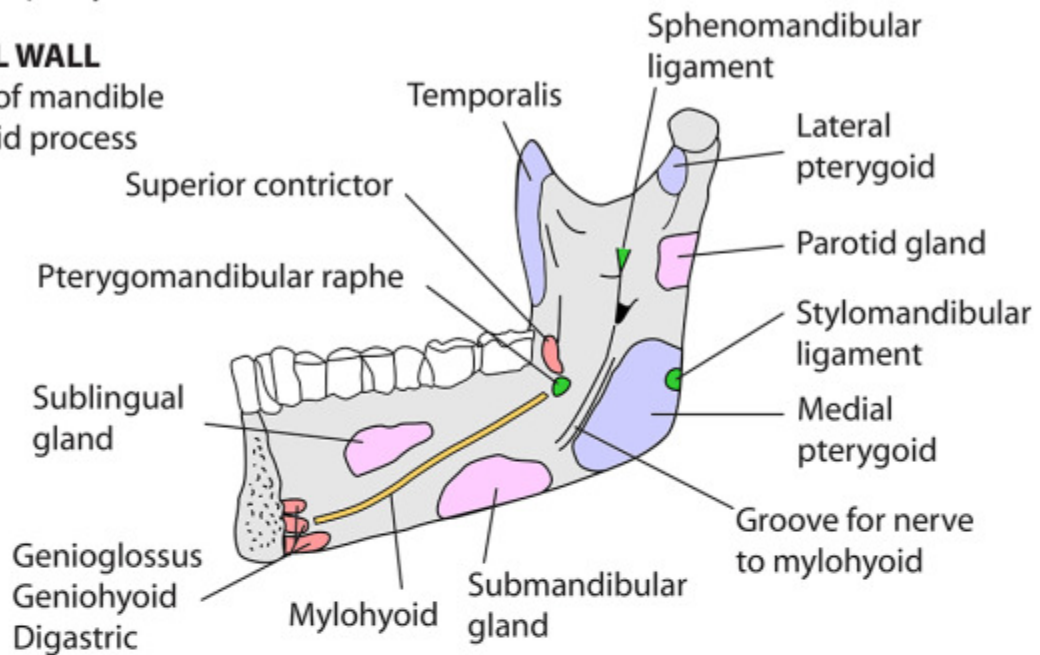
Other structures shown: temporal bone (J), greater wing of sphenoid (K), Temporal branch of VII (L) zygomatic branch of VII (M)

INFRATEMPORAL FOSSA - BOUNDARIES

- Base of skull
- Between pharynx & ramus of mandible

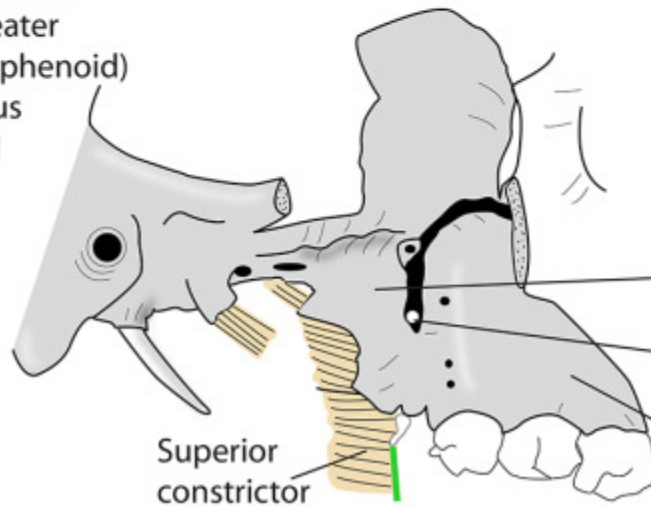
LATERAL WALL

- Ramus of mandible
- Coronoid process



ROOF

- Infratemporal crest (greater wing of sphenoid)
- Squamous temporal



MEDIAL WALL

- Tensor palati
- Levator palati
- Superior constrictor
- Lateral pterygoid plate
- Pterygomaxillary fissure
- Maxilla

POSTERIOR WALL

- Carotid sheath

ANTERIOR WALL

- Posterior maxilla
- Inferior orbital fissure

INFRATEMPORAL FOSSA - CONTENTS

CONTENTS

- Pterygoid muscles
- Fat
- Insertion of temporalis
- Chorda tympani
- Posterior superior alveolar branches of Vb (maxillary branch of trigeminal)
- Pterygoid venous plexus
- Mandibular nerve & branches
- Otic ganglion
- Maxillary artery & branches

Deep temporal arteries & nerves

Auriculo-temporal nerve

Superficial temporal artery

Maxillary artery

External carotid artery

Nerve to mylohyoid

Temporalis

LP

LP

MP

Lingual nerve

Inferior alveolar nerve & artery

Maxillary nerve (Vb)

Posterior superior alveolar nerves & arteries

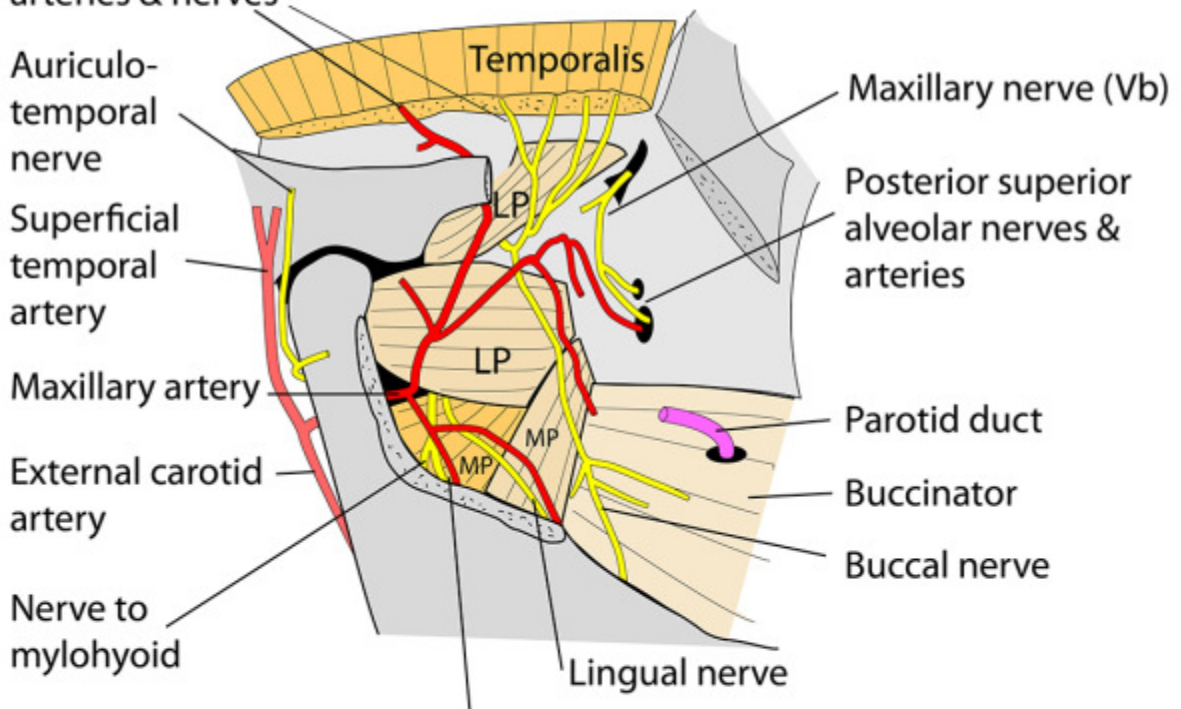
Parotid duct

Buccinator

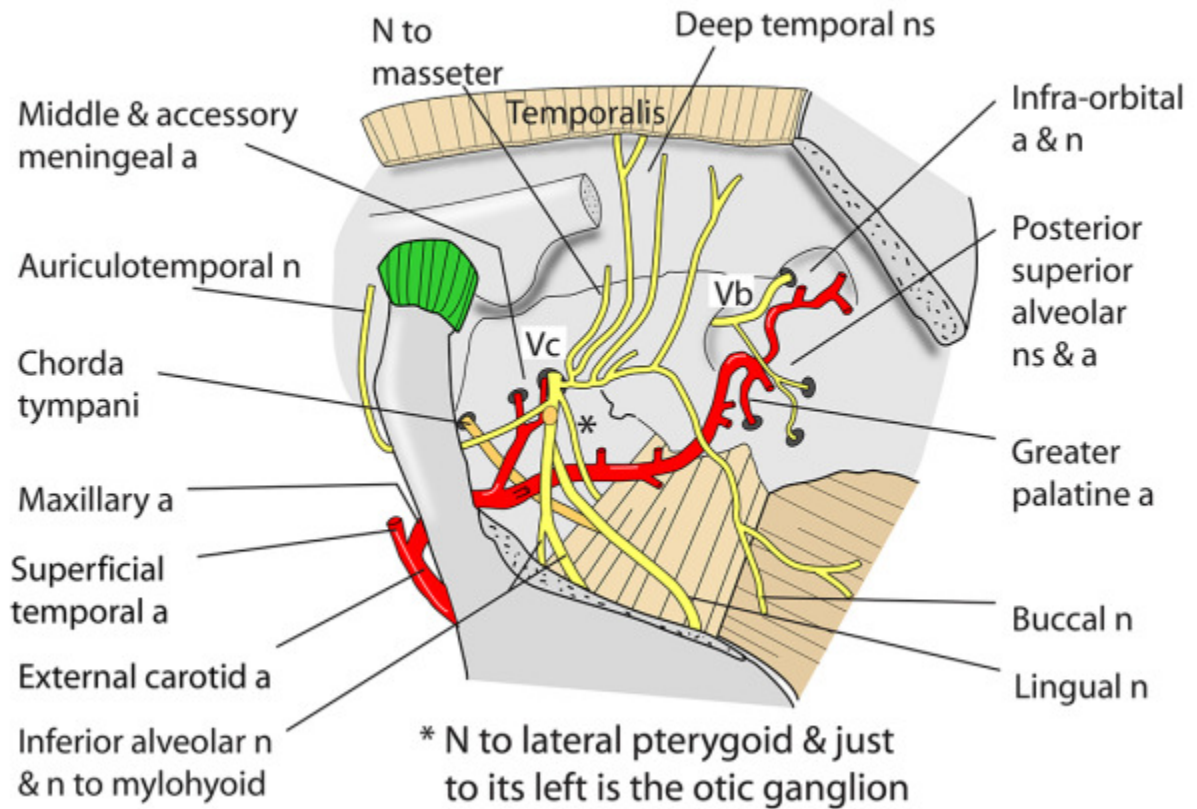
Buccal nerve

SUPERFICIAL DISSECTION

LP = lateral pterygoid
MP = medial pterygoid



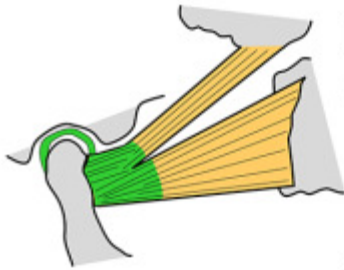
INFRATEMPORAL FOSSA - DEEP DISSECTION



MUSCLES OF MASTICATION

- Temporalis
- Masseter
- Medial pterygoid
- Lateral pterygoid

- All supplied by:
- Mandibular division of Trigeminal (Vc)
 - All derived from 1st pharyngeal arch



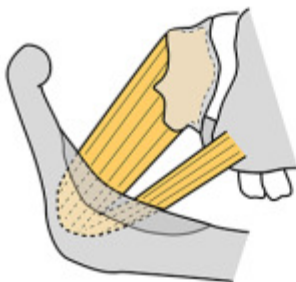
LATERAL PTERYGOID

Arises: 2 heads

Upper: infratemporal surface sphenoid
Lower: lateral surface of lateral pterygoid plate

Inserts: pterygoid fossa below head of mandible, disc, and capsule of temporomandibular joint

Action: protrudes jaw and opens mouth



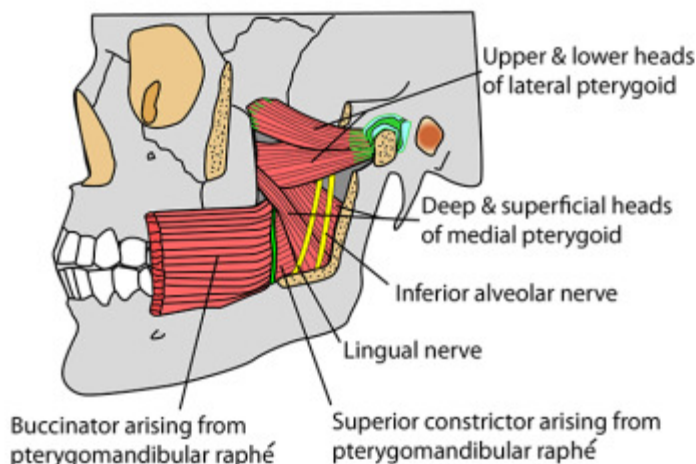
MEDIAL PTERYGOID

Arises: 2 heads

Deep: medial side of lateral pterygoid plate and fossa between plates
Superficial: smaller. Tuberosity of maxilla and pyramidal process of palatine bone

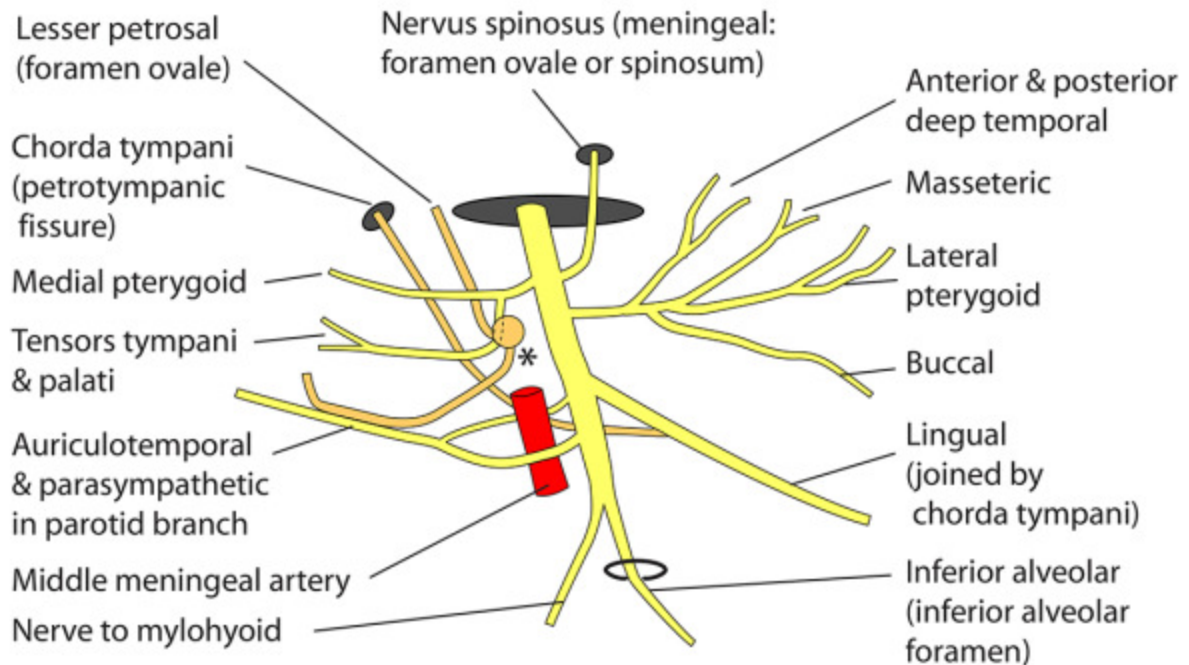
Inserts: Medial ramus of mandible

Action: pulls mandible upwards, forwards and medially (closes mouth and chews)



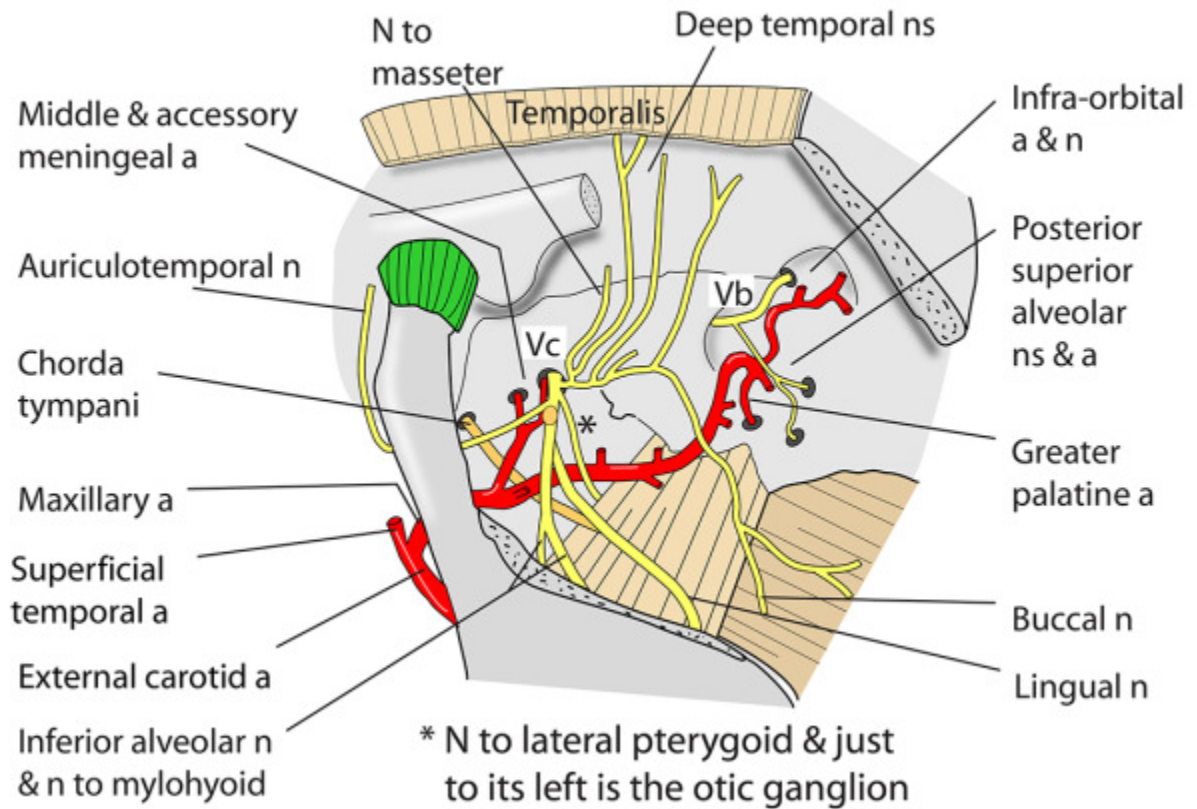
Pterygoid muscles contain venous plexuses that connect with veins both inside (cavernous sinus) and outside the skull (facial veins)

MANDIBULAR DIVISION OF TRIGEMINAL NERVE (Vc), EMERGING FROM FORAMEN OVALE DEEP IN INFRATEMPORAL FOSSA



* Otic ganglion. Parasympathetics from lesser petrosal nerve synapse within it and post-ganglionic fibres are taken to the parotid gland by the auriculotemporal nerve

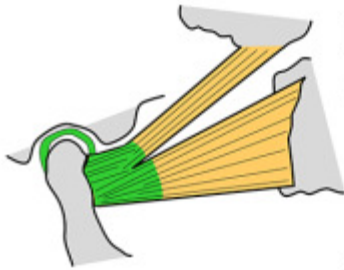
INFRATEMPORAL FOSSA - DEEP DISSECTION



MUSCLES OF MASTICATION

- Temporalis
- Masseter
- Medial pterygoid
- Lateral pterygoid

- All supplied by:
- Mandibular division of Trigeminal (Vc)
 - All derived from 1st pharyngeal arch



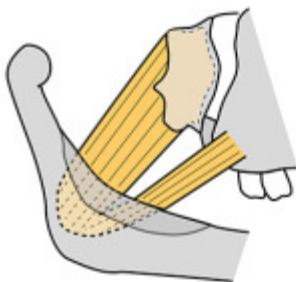
LATERAL PTERYGOID

Arises: 2 heads

Upper: infratemporal surface sphenoid
Lower: lateral surface of lateral pterygoid plate

Inserts: pterygoid fossa below head of mandible, disc, and capsule of temporomandibular joint

Action: protrudes jaw and opens mouth



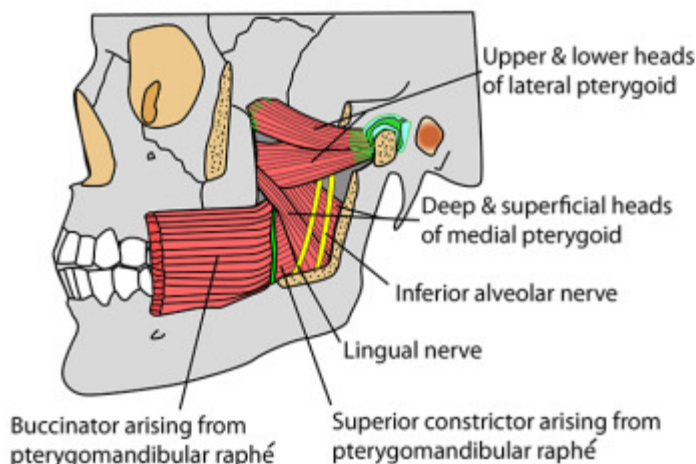
MEDIAL PTERYGOID

Arises: 2 heads

Deep: medial side of lateral pterygoid plate and fossa between plates
Superficial: smaller. Tuberosity of maxilla and pyramidal process of palatine bone

Inserts: Medial ramus of mandible

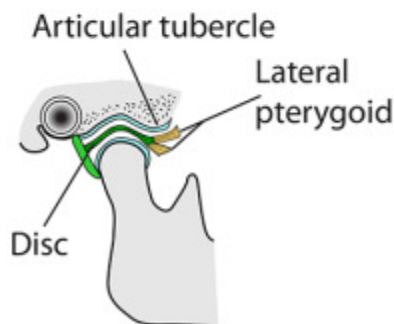
Action: pulls mandible upwards, forwards and medially (closes mouth and chews)



Pterygoid muscles contain venous plexuses that connect with veins both inside (cavernous sinus) and outside the skull (facial veins)

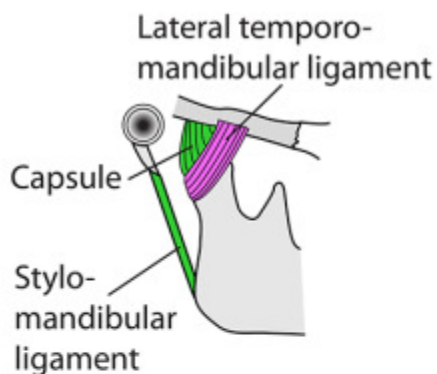
TEMPOROMANDIBULAR JOINT 1

- Synovial
- Condylloid
- Hemicylindrical
- Atypical (fibrocartilage on surfaces)
- Fibrocartilaginous disc
- Synovial membrane lines capsule
- Nerve supply: Auriculotemporal & nerve to masseter



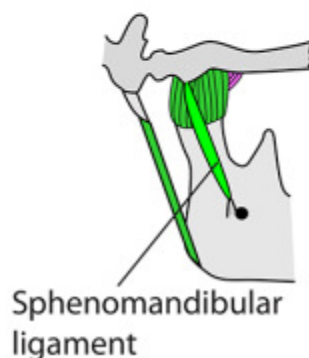
BETWEEN mandible & mandibular fossa of squamous temporal bone

DISC attached anteriorly to head of mandible, thus moves forward with it. Also at lateral pterygoid plate and capsule



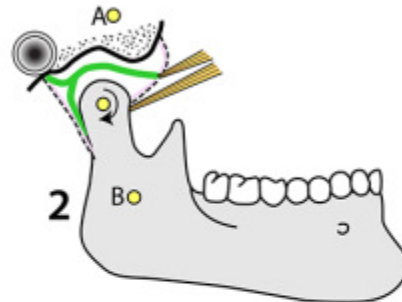
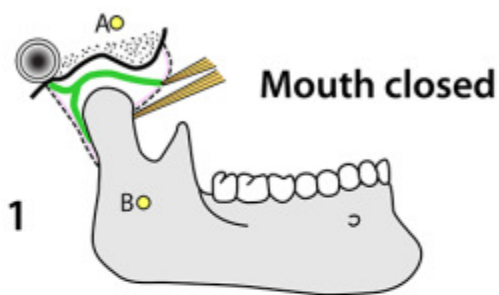
CAPSULE attached to neck of mandible at articular margin. Anterior - at articular tubercle. Posterior - at squamotympanic fissure. Strong but lax at rest

LATERAL TEMPOROMANDIBULAR LIGAMENT from zygomatic arch to posterior neck & ramus of mandible. Fuses with capsule, lax at rest, tightens with any movement



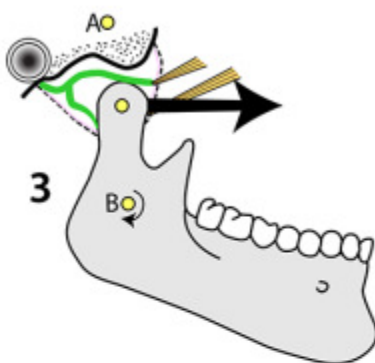
MOVEMENT in upper compartment is protraction (lateral pterygoids), retraction (posterior temporalis) & gliding side to side. In lower compartment is opening (lateral pterygoids & digastrics) & closing (masseters, medial pterygoids & temporalis)

TEMPOROMANDIBULAR JOINT 2

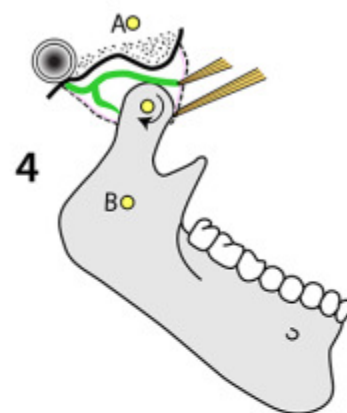


Points A & B represent the 2 ends of the sphenomandibular ligament (spine of sphenoid to lingula of mandible). Distance between them must remain constant at all positions of the joint. Axis for opening must pass through lingula (B) on each side

First few degrees of opening: Rotation only in lower cavity. Mostly gravity



Majority of opening: Further rotation in lower joint cavity. Major degree of anterior displacement of head of mandible onto articular tubercle achieved by lateral pterygoid & occurring in upper joint cavity



Last few degrees of opening: Further rotation in lower joint cavity only